



HHS Public Access

Author manuscript

JAMA Ophthalmol. Author manuscript; available in PMC 2017 January 22.

Published in final edited form as:

JAMA Ophthalmol. 2015 December ; 133(12): 1438–1444. doi:10.1001/jamaophthalmol.2015.3871.

A Region-of-Interest Approach for Detecting Progression of Glaucomatous Damage With Optical Coherence Tomography

Donald C. Hood, PhD, Daiyan Xin, PhD, Diane Wang, BS, Ravivarn Jarukasetphon, MD, Rithu Ramachandran, BA, Lola M. Grillo, BA, Carlos G. De Moraes, MD, MPH, and Robert Ritch, MD

Department of Psychology, Columbia University, New York, New York (Hood, Xin, Wang, Ramachandran, Grillo); Department of Ophthalmology, Columbia University, New York, New York (Hood, De Moraes); Einhorn Clinical Research Center, New York Eye and Ear Infirmary of Mount Sinai, New York (Jarukasetphon, Ritch)

Abstract

IMPORTANCE—Detecting progression of glaucomatous damage is often challenging.

OBJECTIVE—To test the feasibility of using frequency-domain optical coherence tomography (FD-OCT) and a region-of-interest (ROI) approach to measure progressive changes in glaucomatous damage.

DESIGN, SETTING, AND PARTICIPANTS—Among a group of patients in an institutional glaucoma practice who were likely to show glaucoma progression, eyes with a history of an optic disc hemorrhage (DH) confirmed by stereophotography were followed up with FD-OCT cube scans of the optic disc. All patients underwent FD-OCT scans on at least 2 occasions separated by at least 1 year (mean, 3.45 years; range, 1.42–6.39 years). Because we were not studying the effects of an optic DH, no constraint was placed on the time between the documentation of an optic DH and the first scan used in the analysis.

MAIN OUTCOMES AND MEASURES—After en face images of the FD-OCT scan were aligned based on the blood vessels, circumpapillary images were derived for an annulus 100 μm in width, and the retinal nerve fiber layer (RNFL) thickness profiles were plotted for the first and last visits. The ROI width associated with the optic DH was defined as the region of the RNFL profile below the 1% CI based on healthy norms. The change in the ROI width was compared with the

Corresponding Author: Donald C. Hood, PhD, Department of Psychology, Columbia University, 1190 Amsterdam Ave, 406 Schermerhorn Hall, Mail Code 5501, New York, NY 10027, (dch3@columbia.edu).

Author Contributions: Dr Hood had full access to all the data in the study and takes responsibility for the integrity of the data and the accuracy of the data analysis.

Study concept and design: Hood, Xin, Wang, De Moraes, Ritch.

Acquisition, analysis, or interpretation of data: All authors.

Drafting of the manuscript: Hood, Xin, Wang.

Critical revision of the manuscript for important intellectual content: All authors.

Statistical analysis: Hood, Wang, Grillo, De Moraes.

Obtained funding: Hood, Ritch.

Study supervision: Hood, Xin, Ritch.

Conflict of Interest Disclosures: All authors have completed and submitted the ICMJE Form for Disclosure of Potential Conflicts of Interest. Dr Hood reported receiving equipment and grant funding from Topcon and reported receiving equipment from Heidelberg Engineering. No other disclosures were reported.

change in the global RNFL thickness, which was obtained by averaging the circumpapillary RNFL thickness.

RESULTS—The change in the ROI width (mean [SD], 8.0° [6.4°]; 95% CI, 4.9° to 11.1°; range, −0.7° to 19.3°) was significant ($P < .001$, 2-tailed t test) while the change in the global thickness (mean [SD], 2.40 [5.87] μm ; 95% CI, −0.48 to 5.28 μm) was not significant ($P > .12$, 2-tailed t test). Although 15 of the 16 ROIs increased in width between visits, only 11 showed a decrease in the global RNFL thickness.

CONCLUSIONS AND RELEVANCE—For detecting progression of local RNFL damage in patients with glaucoma, an OCT ROI approach appears superior to the OCT global RNFL thickness measure typically used.

Detecting progression of glaucomatous damage presents a challenge to the physician. Although various approaches have been proposed based on optical coherence tomography (OCT), 2 recent reviews^{1,2} favored retinal nerve fiber layer (RNFL) thickness measures of optic disc scans. However, while the authors of one study¹ preferred measuring changes in the global (mean) RNFL thickness of a circumpapillary region, authors of the other study² argued for analyzing the RNFL thickness maps of the entire region around the disc.

Our approach also measures the RNFL thickness from optic disc scans. However, unlike the global RNFL thickness of circumpapillary scans, we examine the change in a local circumpapillary region of interest (ROI). Although this approach is comparable to the event analysis of serial RNFL thickness maps,^{2,3} it is based on a different principle. In particular, our ROI method is part of a general strategy⁴ that analyses OCT scans in a way similar to that used by a radiologist when analyzing a magnetic resonance imaging or computed axial tomography scan.

To assess the usefulness of this ROI approach, we examined eyes with an optic disc hemorrhage (DH). The objective herein was not to study the effects of optic DH but rather to study a group of eyes known to be prone to glaucoma progression.^{5–8} In particular, we measured the change in the width of the abnormal region of an RNFL thickness near the site of an earlier optic DH. To assure that the same region was studied over time, the OCT scans were aligned based on the location of the blood vessels.

Methods

Study procedures followed the tenets of the Declaration of Helsinki, and the protocol was approved by the institutional review boards of Columbia University and the New York Eye and Ear Infirmary of Mount Sinai. Patients were selected from an ongoing prospective early glaucoma study between the 2 institutions. Written informed consent was obtained from all participants, and the protocol adhered to the tenets of the Declaration of Helsinki.

Participants

Sixteen eyes from 16 patients with glaucoma (mean [SD] age, 56.8 [10.6] years) with an optic DH confirmed on stereophotography and with refractive error within ± 6 diopters were included in the study. For each patient, the Table summarizes the diagnosis and the mean

deviation of 24-2 Humphrey visual fields. As expected,⁹⁻¹¹ most eyes (13 of 16) had an optic DH in the inferotemporal region of the disc. All eyes underwent frequency-domain OCT (FD-OCT) cube scans of the optic disc (3D OCT-1000; Topcon) obtained on at least 2 occasions separated by at least 1 year (mean, 3.45 years; range, 1.42–6.39 years). Both scans had to occur after the appearance of an optic DH on stereophotography. An optic DH was defined as a splinter-like or flame-shaped hemorrhage on or within the RNFL or neuroretinal rim, as identified by a glaucoma specialist (R.R.). The appearance of an optic DH was used to identify a region that would likely show glaucoma progression. Because we were not studying the effects of an optic DH, no constraint was placed on the time between the documentation of an optic DH and the first scan used in the analysis, which was obtained 3 days to 8.3 years (median, 78 days) after the identification of an optic DH.

ROI Approach

The borders of the RNFL were determined with a commercial software program (SSV; Topcon). If needed, the borders were then manually corrected by one of us (D.W.) masked to the study objective and chronological sequence of the scans.

For each eye, en face images of the first and last disc cube scans (6×6 mm, 3D OCT-2000; Topcon) were registered by centering both scans on the optic disc center and then rotating to align the blood vessels. After the alignment, circumpapillary images (Figure 1A) were derived for an annulus 100 μ m in width, and the RNFL thickness profiles (Figure 1B) were plotted for the first (dashed lines) and last or most recent (solid lines) visits. The RNFL profiles are shown with the temporal quadrant in the center,⁴ where 0° corresponds to the 9-o'clock position (right eye) and the 3-o'clock position (left eye).

The abnormal region closest to the optic DH was considered the ROI. This approach was used based on the knowledge that glaucoma progression usually occurs because of the development of a new defect or the expansion of a preexisting one (or a combination of both). The width of this ROI was defined as the portion of the scan below the 1% CI based on healthy norms (red region in Figure 1B). The widths (in degrees) of the ROI (blue and red horizontal bars in Figure 1A) for the first and last visits were obtained. A custom software program (MATLAB; MathWorks) determined the alignment of the images, the definition of the ROI, and the ROI width.

Results

Three of the 16 ROIs were in the superior half of the disc, and 13 were in the inferior half. The blue and red horizontal bars in Figure 2 show the locations and widths of the abnormal ROIs for the first (blue) and last (red) visits. The 13 ROIs in the lower half of the disc were in the inferior portion of the temporal quadrant and the temporal portion of the inferior quadrant. The 3 ROIs in the upper half of the disc were in the temporal half of the superior quadrant. In 14 eyes, the region of the disc affected included the portion of the disc associated with the macula ($\pm 8^\circ$ of central vision).¹²⁻¹⁴

Fifteen of the 16 ROIs increased in width between visits, and 1 ROI (patient 3 in the Table) decreased by less than 1°. The ROI widths varied from 7.4° to 61.4° (mean [SD], 24.8°

[14.3°]) for the first visit and from 19.0° to 68.1° (mean [SD], 32.8° [16.3°]) for the last visit. The ROI width changed by a mean (SD) of 8.0° (6.4°) (95% CI, 4.9° to 11.1°) (range, -0.7° to 19.3°). This increase was significant ($P < .001$, 2-tailed t test).

In contrast, the global thickness decreased by a mean (SD) of 2.40 (5.87) μm (95% CI, -0.48 to 5.28 μm), which was not significant ($P > .12$, 2-tailed t test). In addition, fewer eyes (11 of the 16) showed a decrease in the global RNFL thickness.

All eyes underwent a second OCT imaging session on day 1 of testing. These scans can be used to obtain a sense of whether the change for an individual eye is statistically reliable. The ROI width of 8 of 16 eyes exceeded the 2-tailed 95% CI based on the results of the second scans, which showed a mean (SD) width of -0.04° (3.78°), while the ROI width in none of the eyes was less than the 2-tailed 95% CI. In contrast, the global RNFL thickness of 3 eyes was less than the 2-tailed 95% CI based on the results of the second scans, which demonstrated a mean (SD) of 0.11 (2.61) μm , although the global thickness of 1 eye was thicker than the 2-tailed 95% CI.

Discussion

While the global (mean) RNFL thickness is a commonly used OCT measure for assessing glaucoma progression,¹ we hypothesized that an ROI approach would be superior for assessing progression of local damage. The results herein support this hypothesis. There are 2 possible reasons why this approach has not been widely used.

The first concerns the placement of the circle used to derive the RNFL thickness plot. If circle scans are used, they will not necessarily be in the same location for the earlier and later scans unless the OCT imaging system has eye-tracking capability. When cube scans are used to derive a circumpapillary RNFL thickness, as in this study, the alignment can still be off because of torsion of the eye or failure to correctly identify the same center of the eye. Herein, we overcame this problem by registering the images so that the blood vessels were aligned.

The second concerns the nature of glaucomatous damage, which can be diffuse and local, even in the macula and early in the disease process.¹⁵⁻¹⁸ In cases of purely diffuse damage, a global measure may be more suitable. However, diffuse damage is often accompanied by local damage, and an ROI approach is useful in these patients.

The RNFL thickness change map that is a capability of the imaging system's glaucoma progression analysis (CIRRUS; Carl Zeiss Meditec) allows for assessing local changes in the RNFL thickness.³ However, our approach has the advantage of providing a single metric of progression of damage. In addition, it encourages direct viewing of the scan. The OCT scans have better spatial resolution than the magnetic resonance imaging or computed axial tomography scans, but many glaucoma specialists focus on the summary statistics instead of the scan itself. Hood and Raza⁴ have argued that the circumpapillary scan should be viewed directly for 2 reasons. First, it allows the physician to assess if the borders of the RNFL have been correctly identified (segmented) by the automated algorithm. Second, it allows for direct visualization of local damage missed by other methods.^{4,19} However, our approach

has the disadvantage of examining only one location, a circle with a 3.45-mm diameter. Leung et al³ provided evidence that a 4-mm diameter would be better for detecting progression of damage. In addition, the ROI analysis could be applied to derived circle scans of different widths.

Our study had several limitations. It was designed to provide a proof of concept for an ROI approach as opposed to the global RNFL thickness. However, to obtain a better measure of the relative accuracy of the 2 methods, more work is needed. In particular, the sensitivity and specificity of a larger group of patients should be measured using an event-based approach with second measures on different days or a trend-based approach in which eyes are followed up with more frequent tests and perhaps for a longer period.

In addition, we only included regions and eyes with a history of an optic DH. Although this limitation was convenient for a proof-of-concept study, a larger sample should include eyes without a history of an optic DH, which raises the question of how to define an ROI in these eyes. As in the present study, we suggest defining an ROI as the portion of the scan below the 1% CI based on healthy norms. However, instead of restricting the ROI to the region near an optic DH, we suggest defining it as any region beyond a certain criterion width and perhaps depth. For comparison with visual fields, it might be useful to also restrict the ROI to the temporal half of the disc. More work is needed to optimize the criteria for the width or depth of the ROI. We avoided using depth as a criterion because many of the defects had already reached a minimum RNFL thickness. However, the area within the abnormal region (red in Figure 1B) should be explored as a possible alternative to the width of this region. Our ultimate goals are to automate the definition of the ROI on baseline scans and to provide the physician with an indication of the change in the ROI on subsequent visits.

Other methods that use more of the information in the disc cube scan (eg, the glaucoma progression analysis³) should be compared with the ROI method. Our bias herein was to include an en face analysis in future studies. In collaboration with Fortune et al²⁰ and using specialized software they developed, Hood et al²¹ recently showed that an en face slab analysis of swept-source OCT can reveal details of glaucomatous damage not visible on the RNFL thickness plots. In the Hood et al study,²¹ en face images based on the mean reflectance intensity were generated from 52- μ m slabs just below the vitreous border of the inner limiting membrane. To illustrate this en face slab technique, we examined data for patient 4 in the Table, an eye for which we had swept-source OCT scans for both the first and last visits. Figure 3A shows the FD-OCT RNFL profiles for this eye in the same format as in Figure 1B. The en face slab image based on the swept-source OCT scan from the first visit is shown in Figure 3B. Figure 3C (left) shows an enlargement of the region within the red square in Figure 3B, and Figure 3C (right) shows the same region for the last visit. The tips of the green arrowheads indicate the same locations in all panels. The small increase in width seen in Figure 3A corresponds to the change in contrast seen in the regions just to the left of the blood vessels (green arrowheads). These changes are easier to see in the locations farther from the disc, such as the regions indicated by the white arrows, which are in the same locations. While these results are preliminary, they support the suggestion that an en face slab analysis may be clinically useful.²¹

Conclusion

For detecting progression of local RNFL damage in patients with glaucoma, an OCT ROI appears superior to the OCT global RNFL thickness measure typically used.

Acknowledgments

Funding/Support: This study was supported by grant RO1-EY-02115 from the National Institutes of Health, by an equipment grant from Topcon, and by the Larry Stromfeld Glaucoma Research and Development Fund of the New York Eye and Ear Infirmary of Mount Sinai.

Role of the Funder/Sponsor: The funding sources had no role in the design and conduct of the study; collection, management, analysis, and interpretation of the data; preparation, review, or approval of the manuscript; and decision to submit the manuscript for publication.

References

1. Bussell II, Wollstein G, Schuman JS. OCT for glaucoma diagnosis, screening and detection of glaucoma progression. *Br J Ophthalmol*. 2014; 98(suppl 2):ii15–ii19. [PubMed: 24357497]
2. Leung CK. Diagnosing glaucoma progression with optical coherence tomography. *Curr Opin Ophthalmol*. 2014; 25(2):104–111. [PubMed: 24370973]
3. Leung CK, Yu M, Weinreb RN, Lai G, Xu G, Lam DS. Retinal nerve fiber layer imaging with spectral-domain optical coherence tomography: patterns of retinal nerve fiber layer progression. *Ophthalmology*. 2012; 119(9):1858–1866. [PubMed: 22677426]
4. Hood DC, Raza AS. On improving the use of OCT imaging for detecting glaucomatous damage. *Br J Ophthalmol*. 2014; 98(suppl 2):ii1–ii9. [PubMed: 24934219]
5. Kim JM, Kyung H, Azarbod P, Lee JM, Caprioli J. Disc haemorrhage is associated with the fast component, but not the slow component, of visual field decay rate in glaucoma. *Br J Ophthalmol*. 2014; 98(11):1555–1559. [PubMed: 24990873]
6. Ernest PJ, Schouten JS, Beckers HJ, Hendrikse F, Prins MH, Webers CA. An evidence-based review of prognostic factors for glaucomatous visual field progression. *Ophthalmology*. 2013; 120(3):512–519. [PubMed: 23211636]
7. Suh MH, Park KH, Kim H, et al. Glaucoma progression after the first-detected optic disc hemorrhage by optical coherence tomography. *J Glaucoma*. 2012; 21(6):358–366. [PubMed: 21623225]
8. De Moraes CG, Demirel S, Gardiner SK, et al. Rate of visual field progression in eyes with optic disc hemorrhages in the ocular hypertension treatment study. *Arch Ophthalmol*. 2012; 130(12):1541–1546. [PubMed: 23229692]
9. Airaksinen PJ, Mustonen E, Alanko HI. Optic disc hemorrhages: analysis of stereophotographs and clinical data of 112 patients. *Arch Ophthalmol*. 1981; 99(10):1795–1801. [PubMed: 7295129]
10. Healey PR, Mitchell P, Smith W, Wang JJ. Optic disc hemorrhages in a population with and without signs of glaucoma. *Ophthalmology*. 1998; 105(2):216–223. [PubMed: 9479278]
11. Yamamoto T, Iwase A, Kawase K, Sawada A, Ishida K. Optic disc hemorrhages detected in a large-scale eye disease screening project. *J Glaucoma*. 2004; 13(5):356–360. [PubMed: 15354071]
12. Hood DC, Raza AS, de Moraes CGV, et al. Initial arcuate defects within the central 10 degrees in glaucoma. *Invest Ophthalmol Vis Sci*. 2011; 52(2):940–946. [PubMed: 20881293]
13. Hood DC, Raza AS, de Moraes CGV, Johnson CA, Liebmann JM, Ritch R. The nature of macular damage in glaucoma as revealed by averaging optical coherence tomography data. *Transl Vis Sci Technol*. 2012; 1(1):3.
14. Hood DC, Raza AS, de Moraes CGV, Liebmann JM, Ritch R. Glaucomatous damage of the macula. *Prog Retin Eye Res*. 2013; 32:1–21. [PubMed: 22995953]
15. Artes PH, Chauhan BC, Keltner JL, et al. Ocular Hypertension Treatment Study Group. Longitudinal and cross-sectional analyses of visual field progression in participants of the Ocular

- Hypertension Treatment Study. *Arch Ophthalmol*. 2010; 128(12):1528–1532. [PubMed: 21149774]
16. Henson DB, Artes PH, Chauhan BC. Diffuse loss of sensitivity in early glaucoma. *Invest Ophthalmol Vis Sci*. 1999; 40(13):3147–3151. [PubMed: 10586936]
 17. Hood DC, Slobodnick A, Raza AS, de Moraes CG, Teng CC, Ritch R. Early glaucoma involves both deep local, and shallow widespread, retinal nerve fiber damage of the macular region. *Invest Ophthalmol Vis Sci*. 2014; 55(2):632–649. [PubMed: 24370831]
 18. Jeong JS, Kang MG, Kim CY, Kim NR. Pattern of macular ganglion cell–inner plexiform layer defect generated by spectral-domain OCT in glaucoma patients and normal subjects [published online February 25]. *J Glaucoma*. 2015
 19. Xin D, Talamini CL, Raza AS, et al. Hypodense regions (holes) in the retinal nerve fiber layer in frequency-domain OCT scans of glaucoma patients and suspects. *Invest Ophthalmol Vis Sci*. 2011; 52(10):7180–7186. [PubMed: 21791587]
 20. Fortune B, Lusardi TA, Reynaud J, et al. Evidence of axonopathy during early-stage experimental glaucoma: relationship between in vivo imaging and histological findings [ARVO E-Abstract]. *Invest Ophthalmol Vis Sci*. 2014; 55:2644.
 21. Hood DC, Fortune B, Mavrommatis MA, et al. Details of glaucomatous damage are better seen on OCT en-face images than on OCT retinal nerve fiber layer thickness maps. *Invest Ophthalmol Vis Sci*. In press.

At a Glance

- Using a region of interest (ROI) approach, optical coherence tomography (OCT) scans on different days need to be aligned.
- An ROI was defined as thinned region of retinal nerve fiber layer (RNFL) on the first test day.
- The ROI width can be tracked over time.
- For patients with optic disc hemorrhage, an ROI approach appears superior to detect glaucoma progression compared with the typically used OCT measure of the global RNFL mean.

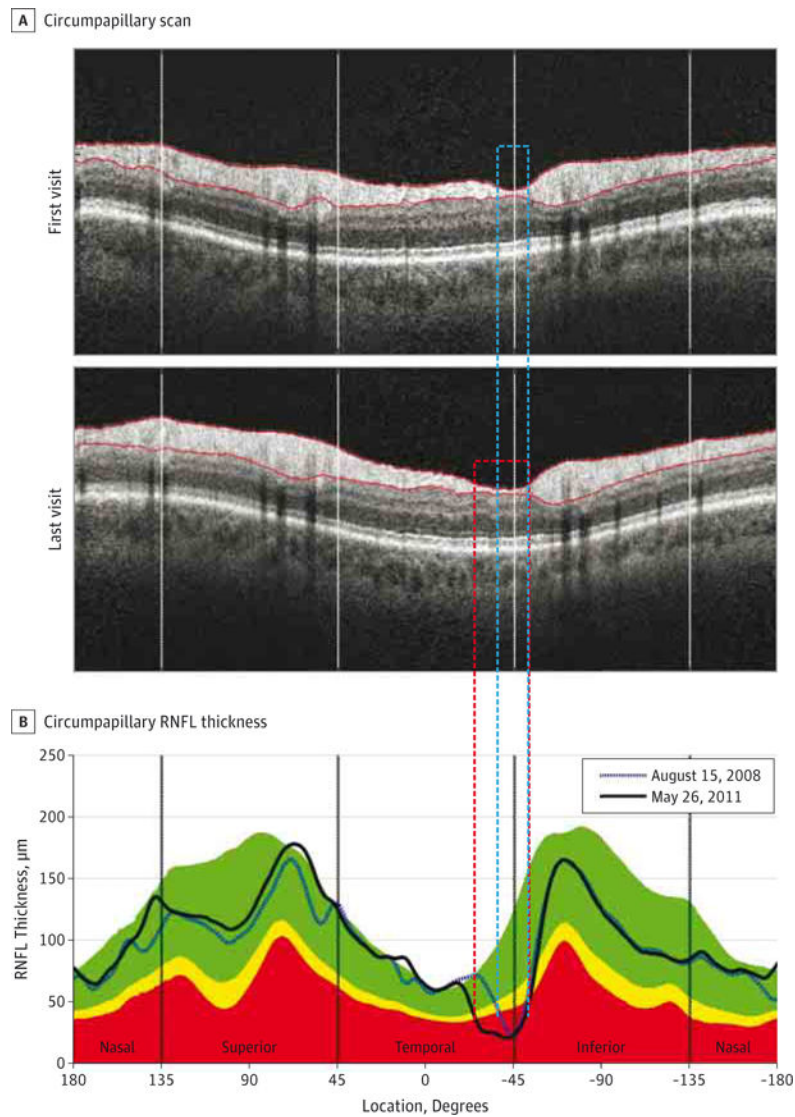


Figure 1. Region-of-Interest Method

A, Shown is a derived circumpapillary scan after the alignment from the first and last visits for patient 2 in the Table. B, The circumpapillary retinal nerve fiber layer (RNFL) thickness is shown for the first (August 15, 2008) and last (May 26, 2011) visits. Where 0° corresponds to the 9-o'clock and 3-o'clock positions in the right and left eyes, respectively. See the ROI Approach subsection of the Methods section for an explanation of the regions of interest.

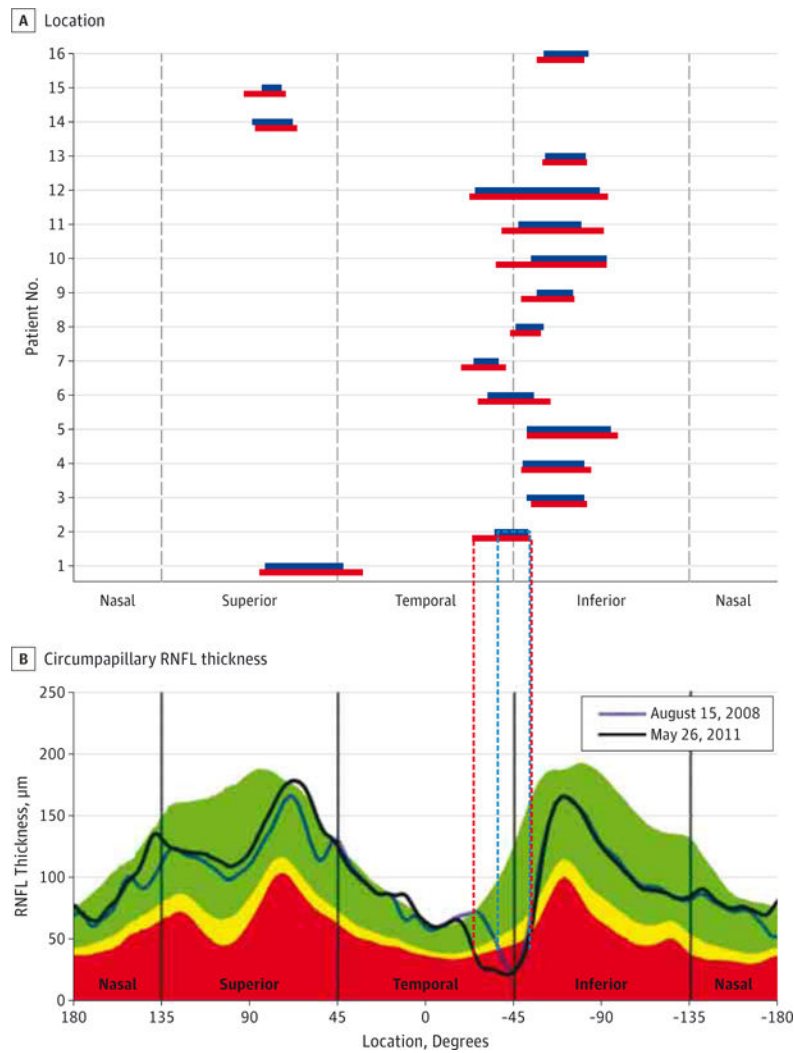


Figure 2. Region-of-Interest Width at the First and Last Visits

A, Shown is the region-of-interest at the first (blue horizontal bars) and last (red horizontal bars) visits as a function of the distance around the optic disc for the patients in the Table. B, The circumpapillary retinal nerve fiber layer (RNFL) thickness is shown for the first (August 15, 2008) and last (May 26, 2011) visits. Where 0° corresponds to the 9-o'clock and 3-o'clock positions in the right and left eyes, respectively. See the ROI Approach subsection of the Methods section for an explanation of the regions of interest.

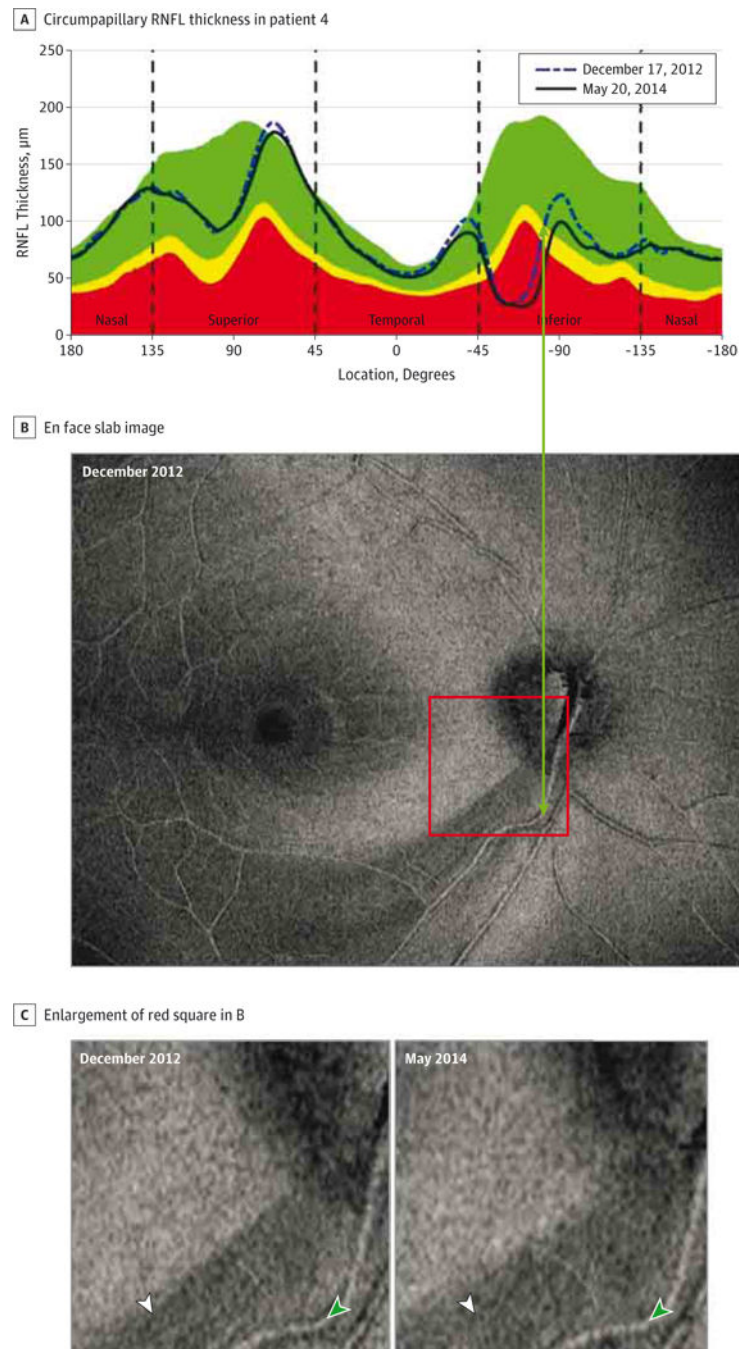


Figure 3. An Example of Progression Seen on En Face Slab Images

A, The circumpapillary retinal nerve fiber layer (RNFL) thickness is shown for patient 4 in the Table for the first (December 17, 2012) and last (May 20, 2014) visits. An en face slab image is shown. C and D, Shown is an enlargement of the region within the red square in B. The white arrowheads in C point to the same location and provide a reference to assess the progression of damage. The green arrowheads point to the same location in all panels.

Table

Patient Diagnoses and Visual Field Mean Deviation Values

Patient No.	Eye	Diagnosis	24-2 Humphrey Visual Field Mean Deviation, dB	
			First Visit	Last Visit
1	Left	PG	-8.28	-13.18
2	Right	POAG	-0.88	-2.28
3	Right	XFG	0.64	0.44
4	Right	POAG	-8.71	-16.31
5	Right	POAG	-8.41	-8.79
6	Left	POAG	-1.59	-1.67
7	Right	POAG	0.38	-1.98
8	Right	POAG	-1.83	-2.39
9	Right	POAG	-0.05	-1.11
10	Right	POAG	-5.45	-7.95
11	Right	POAG	-3.01	-7.71
12	Right	POAG	-15.39	-15.32
13	Right	POAG	-1.12	-1.04
14	Right	POAG	-6.85	-10.17
15	Right	POAG	-7.75	-9.32
16	Left	POAG	-2.85	-3.58

Abbreviations: PG, pigmentary glaucoma; POAG, primary open-angle glaucoma; XFG, exfoliation glaucoma.

Author Manuscript

Author Manuscript

Author Manuscript

Author Manuscript